

Urinary Myiasis Caused by *Clogmia albipunctata* from the Palestinian Territories

Myiases urinaires dues à *Clogmia albipunctata* dans les territoires palestiniens

D. Hjaija · S. S. Sawalha · Z. S. Amr · A. Katbeh-Bader · R. A.H. Hassoon

Received: 8 August 2018; Accepted: 30 August 2018
© Société de pathologie exotique et Lavoisier SAS 2018

Abstract This is the first record of a case of urinary myiasis in the Palestinian Territories caused by *Clogmia albipunctata*. Larvae were discharged through urine by a 28-year-old pregnant female whom complained of mild abdominal pain associated with burning sensation while urinating over the past 3 months. Detailed description of the larva was provided.

Keywords *Clogmia albipunctata* · Human myiasis · Urinary tract · Palestinian Territories · Western Asia

Résumé Il s'agit du premier cas de myiase urinaire dans les Territoires palestiniens due à *Clogmia albipunctata*. Les larves ont été excrétées dans les urines d'une patiente de 28 ans, enceinte, qui se plaignait de douleurs abdominales légères associées, les trois derniers mois, à une sensation de brûlure lors des mictions. Cet article présente également la description des larves.

Mots clés *Clogmia albipunctata* · Myiase humaine · Voies urinaires · Territoires palestiniens · Asie du Sud-Ouest

D. Hjaija · R. A.H. Hassoon
Director of Preventive Medicine Department,
Palestinian Ministry of Health, Ramallah, Palestine

S. S. Sawalha
Environmental Health Department, Ministry of Health,
Ramallah, Palestine

Z. S. Amr (✉)
Department of Biology, Jordan University of Science &
Technology, Irbid, Jordan
e-mail : amrz@just.edu.jo

A. Katbeh-Bader
Department of Plant Protection,
University of Jordan, Amman, Jordan

Introduction

Several forms of myiasis due to dipteran larvae infestation to human tissues or organs are known [18,19]. Urinary myiasis is considered a rare form caused by several species of dipterans in different countries [1,4,7,9,11,12,17,18]. *Clogmia albipunctata* was found to be associated with urinary myiasis [1,2,4,7].

So far, no forms of human myiasis were reported from the Palestinian Territories. In this communication, we report the first case of urinary myiasis in the Palestinian Territories.

Materials and methods

Case History

A 28-year-old female patient in her 22 weeks of pregnancy was presented to a private clinic with mild abdominal pain associated with burning sensation while urinating over the past 3 months. She has a university degree and is living in the west central part of the West Bank. Upon urine examination, about 20 larvae were collected and preserved in 70% ethyl alcohol. The larvae were discharged eight to ten times during September to the first half of December, 2017.

Antibiotic and antiseptic therapy was given to the patient to prevent secondary bacterial infection, and plentiful oral hydration was recommended in order to expel any larvae in the bladder. Complete recovery of symptoms was observed at the end of post-therapeutic follow-up.

Subsequently, the patient's house was visited, where larvae and adults of moth flies were collected from a cesspool around the house and from inside the house. The bathroom is of the squat traditional type.

Entomological material

About 20 larvae were recovered from the patient. They were washed in distilled water then preserved in 75% ethyl alcohol.

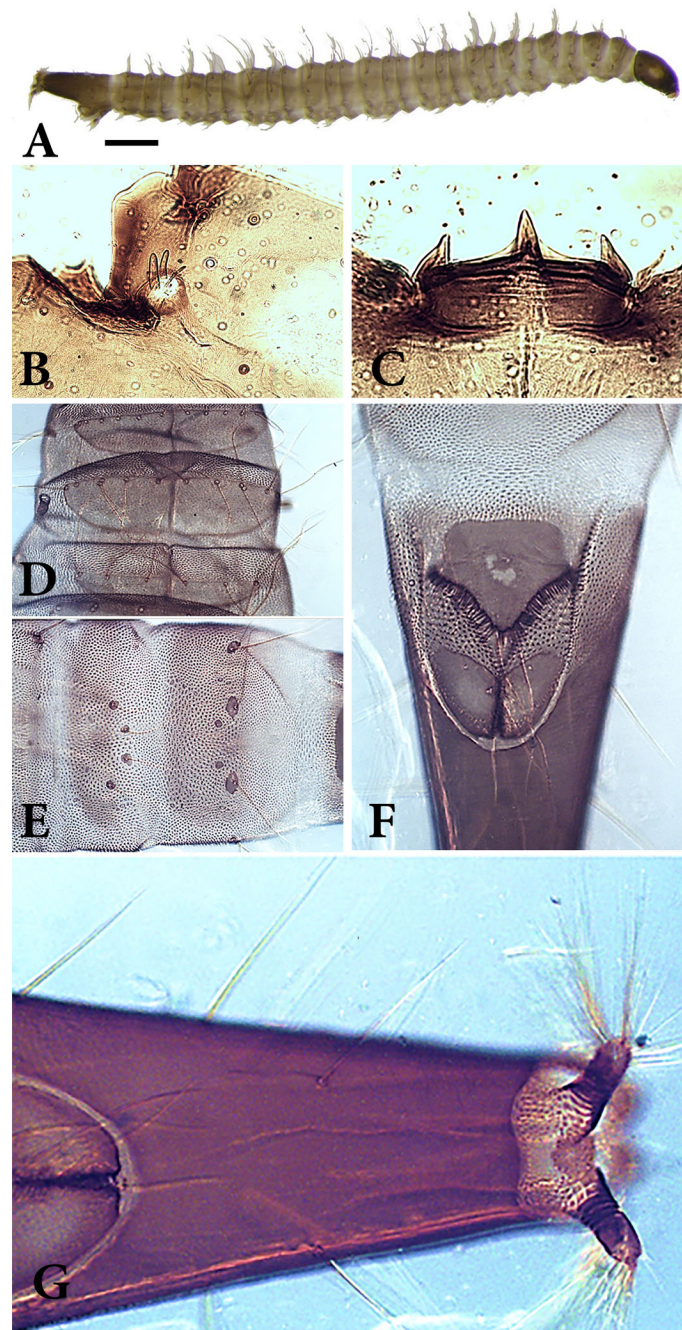


Fig. 1 Fourth instar larva recovered from urine of the patient. **A.** Lateral view of *Clogmia albipunctata* larva recovered from urine of the patient (Scale bar 1mm). **B.** Antenna with 3 sensilla (Magnification 40X). **C.** Mental teeth (Magnification 40X). **D.** First 3 dorsal plates showing the longitudinal sutures and setae distribution (Magnification 40X). **E.** ventral view of abdominal segments 6 and 7 (Magnification 40X). **F.** Anal opening between a pentagonal and 2 triangular lateral sclerites. **G.** Ventral braches of the spiracles surrounded by fine setae (Magnification 40X) / Larve au 4^e stade retrouvée dans les urines de la patiente. **A.** Vue latérale de la larve de *Clogmia albipunctata* retrouvée dans les urines de la patiente (échelle 1 mm). **B.** Antenne avec 3 sensilles (grossissement 40X). **C.** Dents (grossissement 40X). **D.** Trois premières plaques dorsales montrant les sutures longitudinales et la distribution des soies (grossissement 40X). **E.** Vue ventrale des segments abdominaux 6 et 7 (grossissement 40X). **F.** Orifice anal entre une sclérite pentagonale et 2 sclérites triangulaires. **G.** Trachée ventrale des spiracles, entourée de fines soies (grossissement 40X).

Later larvae were mounted in Hoyer's medium, and examined under the microscope.

Results

Microscopic examination revealed that these larvae belongs to the moth fly, *Clogmia albipunctata* (Psychodidae, Diptera) (Fig. 1A). Fourth instar larvae measured about 6-10 mm (average 7.6 mm) in total length. Head is conical, dark brown to black, antennae appear as tiny segment with 2 thick and one thin sensoria (Fig. 1B), mouthparts at the antero-dorsal part of the head capsule, with three, sharp mental teeth (Fig. 1C).

Thorax: prothorax with 2 plates on the dorsal side, the first plate with longitudinal median suture, each side of the plate with seven setae at the anterior margin of the plate, the first four setae from the median suture equally spaced, the remaining three setae are close together and located at the antero-lateral angle, a small sclerite is present at lateral side of the plate bearing 3 setae; the second plate with 6 setae, the third and fourth setae are close together, the spiracles are at the tip of short cylindrical sclerotized tube at the lateral sides of the prothorax (Fig. 1D). **Mesothorax** with two plates the anterior one, with longitudinal suture, each side with 3 equally spaced, long setae located at the anterior margin of the plate, a small sclerite is present at lateral side bearing 4 setae (3 conspicuous distal setae and one proximal inconspicuous setae); the second plate entire (without a suture), with 5 setae, the second and the third are close together. **Metathorax** with same setae as mesothorax but without a suture on the plates, with one seta lateral to the posterior plate.

Abdomen: First segment with two plates dorsally, the anterior plate with two setae, the posterior with 4 setae, and a small sclerite laterally with two setae. Segments 2-7 have three plates; anterior plates with one seta at posterior margin and one seta lateral to the plate, median plate with 2 hairs at the middle, the posterior plate with four setae the 2nd and 3rd close together, a small sclerite is present at lateral side bearing 3-4 setae. Segment eight bears two short dorsal and two long ventral sclerotized branches bearing the spiracles which are surrounded by dense fine hairs (Fig. 1E). The anal opening has a pentagonal sclerites at the antero-ventral side which bears dense long hairs (dark at the base and light at the distal end) and 2 lateral lobes that are distally sclerotized (Figs 1F and G).

Pupae and adults of moth flies collected from a cesspool around the house and from inside the house are illustrated (Figs 2A and B).

Discussion

Several dipterans species have been implicated to cause urinary myiasis including *Psychoda albipennis* [11,17], *Lucilia*



Fig. 2 Pupa and adult *Clogmia albipunctata* recovered from cesspool around the house of the patient. A. Dorsal view of *Clogmia albipunctata* pupa. B. Adult *Clogmia albipunctata* (Scale bar 1 mm / Pupa et adulte de *Clogmia albipunctata* retrouvés dans la fosse septique, près de la maison de la patiente. A. Vue dorsale de la pupa de *Clogmia albipunctata*. B. *Clogmia albipunctata* adulte (échelle 1 mm)

sericata [9], both *Wohlfahrtia magnifica* and *Lucilia sericata* [12]. The present study reports for the first time a case of urinary myiasis in the Palestinian Territories. *Clogmia albipunctata* was found to be associated with urinary myiasis in Japan [7], USA [4], Egypt [1,2] and China [18], as well as nasopharyngeal myiasis [8,10] and intestinal myiasis [13,14]. All cases of urinary natural infestation were among women [1,2,7,18]. This is perhaps due to the physiological and anatomical features of the female urogenital system (including the urethra) as well as to poor hygienic practices employed by some female patients [18].

Fourteen species of moth flies were recorded from historical Palestine [5,7], whereas *Clogmia albipunctata* was collected from several localities. Most species of moth flies breed in bathrooms, toilets, drain pipes or septic tanks and are considered as domestic insects [15]. The life cycle from adult to adult requires 27±5 days, with four instar larvae with average duration of 4 days per stage, and five days for the pupal stage [6]. *Clogmia albipunctata* was considered as potential mechanical vector for 45 bacterial species associated with hospital [3].

It seems that the patient was infested with *C. albipunctata* eggs more than one time, since she discharged larvae over a period of almost three months. Larvae of *C. albipunctata* were collected from septic tanks, cesspools and contaminated water [16]. This perhaps has to do with personal

hygiene practiced by the patients especially those who use the squat traditional type bathrooms, which may be infested with adult moth flies. Precautionary measures to avoid infestation is through high levels of personal hygiene.

Conflict of interest : The authors do not have any conflict of interest to declare.

References

1. El-Badry AA, Salem HK, El-Aziz Edmardash YA (2014) Human urinary myiasis due to larvae of *Clogmia (Telmatoscopus) albipunctata* Williston (Diptera: Psychodidae) first report in Egypt. *J Vector Borne Dis* 51:247–9
2. El-Dib NA, El Wahab WMA, Hamdy DA, Ali MI (2017) Case report of human urinary myiasis caused by *Clogmia albipunctata* (Diptera: Psychodidae) with morphological description of larva and pupa. *J Arthropod-Borne Dis* 11:533–538. eCollection 2017 Dec
3. Faulde M, Spiesberger M (2013) Role of the moth fly *Clogmia albipunctata* (Diptera: Psychodinae) as a mechanical vector of bacterial pathogens in German hospitals. *J Hosp Infect* 83:51–60. doi: 10.1016/j.jhin.2012.09.019. Epub 2012 Nov 22
4. Hyun DY, Cain MP, Blue-Hnidy DE, Conway JH (2004) Urinary myiasis associated with ureteral stent placements. *Pediatr Infect Dis J* 23:179–81
5. Ježek J, Barverman Y (2010) Non-biting moth flies (Diptera: Psychodidae) new to the fauna of Israel. *Acta Univ Carol Biol* 50:57–60
6. Jiménez-Guri E, Wotton KR, Gavilán B, Jaeger J (2014) A staging scheme for the development of the moth midge *Clogmia albipunctata*. *PLoS ONE* 9:e84422.
7. Kamimura K, Arakawa RA (1986) Case report on urinary myiasis due to the moth fly, *Telmatoscopus albipunctata*. *Med Vet Entomol* 37: 161–2. doi: 10.1371/journal.pone.0084422. eCollection 2014
8. Mohammed N, Smith KG (1976) Letter: Nasopharyngeal myiasis in man caused by larve of *Clogmia* (= *Telmatoscopus*) *albipunctatus* Williston (Psychodidae, Dipt.) *Trans R Soc Trop Med Hyg* 70:91
9. Nagy V (2012) Unusual presentation of the urogenital myiasis caused by *Lucilia sericata* (Diptera: Calliphoridae). *Ann Agric Environ Med* 19:802–4
10. Nevill EM, Basson PA, Schoonraad JH, Swanepoel K (1969) A case of nasal myiasis caused by the larvae of *Telmatoscopus albipunctatus* (Williston) 1893 (Diptera: Psychodidae) *S Afr Med J* 43:5124
11. Oğuz U, Reşorlu B, Çizmeci Z, Ünsal A (2012) A rare urogenital myiasis caused by *Psychoda albipennis*: a case report. *Turkish J. Urol* 38:168–9. doi:10.5152/tud.2012.035
12. Salimi M, Goodarzi D, Karimfar MH, Edalat H (2010) Human Urogenital Myiasis Caused by *Lucilia sericata* (Diptera: Calliphoridae) and *Wohlfahrtia magnifica* (Diptera: Sarcophagidae) in Markazi Province of Iran. *Iran J Arthropod Borne Dis* 4:72–6. Epub 2010 Jun 30.
13. Smith KG, Thomas V (1979) Intestinal myiasis in man caused by larvae of *Colgmia* (= *Telmatoscopus*) *albipunctatus* Williston (Psychodidae, Diptera). *Trans R Soc Trop Med Hyg* 73:349–50
14. Tu WC, Chen HC, Chen KM, et al (2007) Intestinal myiasis caused by larvae of *Telmatoscopus albipunctata* in a Taiwanese man. *J Clin Gastroenterol* 41:400–2
15. Verheggen F, Mignon J, Louis J, et al (2008) Mothflies (Diptera: Psychodidae) in hospitals: a guide to their identification and methods for their control. *Acta Clin Belg* 63:251–5
16. Wagner R (1984) On some *Psychodidae* (Diptera) from Israel. *Israel J Entomol* 18:3–10
17. Yenice MG, Demir T, Babür C, et al (2011) A case of urogenital myiasis caused by *Psychoda albipennis* (Diptera: Nematocera). [article en turc] *Mikrobiyol Bul* 45:558–64
18. Zhang B, Wang L, Liu J, et al (2017) Case report: A rare case of urinary myiasis induced by the fourth instar larvae of *Telmatoscopus albipunctatus*. *PLoS Negl Trop Dis* 11:e0006016. doi: 10.1371/journal.pntd.0006016. eCollection 2017 Dec
19. Zumpt F (1965) Myiasis in man and animals in the Old World: a textbook for physicians, veterinarians and zoologists. 1st edn.; London: Butterworths, 267 p